

Primary Uterine Cervical Cancer: Correlation of Preoperative Magnetic Resonance Imaging and Clinical Staging (FIGO) with Histopathology Findings

Zdenko Kraljević¹, Klaudija Visković², Mario Ledinsky³, Dijana Zadavec⁴, Ivan Grbavac¹, Marijana Bilandžija¹, Hrvojka Soljačić-Vraneš¹, Krunoslav Kuna¹, Ksenija Klasnić⁵ and Ivan Krolo⁴

¹ University of Zagreb, »Sestre milosrdnice« University Hospital Center, Department of Gynaecology and Obstetrics, Zagreb, Croatia

² University of Zagreb, University Hospital for Infectious Diseases, Department of Radiology and Ultrasound, Zagreb, Croatia

³ University of Zagreb, »Sestre milosrdnice« University Hospital Center, Department of Surgery, Zagreb, Croatia

⁴ University of Zagreb, »Sestre milosrdnice« University Hospital Center, Department of Diagnostic and Interventional Radiology, Zagreb, Croatia

⁵ University of Zagreb, Faculty of Humanities and Social Sciences, Department of Sociology, Zagreb, Croatia

ABSTRACT

The most commonly used staging system for cervical cancer is based on the International Federation of Gynaecology and Obstetrics (FIGO) staging system. Magnetic resonance imaging (MRI) has been accepted as the optimal tool for evaluation of the main prognostic factors and selection of therapeutic strategy. The purpose of this study was to compare the preoperative clinical examination FIGO staging findings with MRI and postoperative pathology report in females with primary cancer of the cervix. The study prospectively included 46 females consecutively hospitalized at the Department of Gynaecology and Obstetrics at the »Sestre milosrdnice« University Hospital Center in Zagreb. Interviews, clinical examination, transvaginal ultrasound and MRI were performed in all patients. In selected patients the surgical procedure was done and the correlation of clinical findings according to FIGO classifications, MRI and histopathological findings was completed. According to FIGO classification, positive clinical findings for stage IIA were found in 26/46 (55.5%) and stage IIB in 20/46 (44.5%) patients. FIGO MR modified classification confirmed stage IIA in 30/46 (66.6%) and stage IIB in 16/46 (33.4%) patients. Surgery (Wertheim radical hysterectomy with bilateral pelvic and selective para-aortic lymphadenectomy) was performed in 33/46 (71%) patients with clinically, MR, cytologically and pathohistologically confirmed findings of cervical cancer: 26 patients with IIA clinically FIGO stage and 7 with IIB stage. MRI examination proved better than clinical examination in staging of cervical carcinoma with 90.9% versus 79.0% accuracy rate. We suggest the application of the following MR protocol in all clinically staged FIGO IIA and IIB patients: T1W, T2WI and postcontrast dynamic T1WI after 3 and 60 seconds and after 5 minutes, performed on 1.5T MR machine.

Key words: cervical cancer, magnetic resonance imaging, staging

Introduction

Cervical cancer is the second most common cancer in women worldwide¹. The highest incidence in Europe is observed in Eastern European countries². According to data from the Croatian National Institute of Public Health, the incidence of cervical cancer in Croatia was 16.8/100,000 in 2007³. Croatia has a lower incidence of

the disease than most Central and Eastern European countries⁴ but still much higher than most Western European countries⁵. Advances in surgical treatment, radiation treatment and chemotherapy require an accurate staging system.

The most commonly used staging system for cervical cancer is based on the International Federation of Gynaecology and Obstetrics (originally in French: *Fédération Internationale de Gynécologie et d'Obstétrique* (FIGO)) staging system^{6,7}. FIGO was founded in 1957 in Geneva. This system is based on findings that include clinical examination, chest radiography, intravenous, barium enema studies, cystoscopy and proctoscopy⁸. Without cross-sectional imaging, there is a poor evaluation of deep pelvic invasion⁸. Magnetic resonance imaging (MRI) is now widely accepted as optimal tool for evaluation of the main prognostic factors and selection of therapeutic strategy⁹.

The aim of this paper was to compare the preoperative clinical examination FIGO staging findings with MRI and postoperative pathology reports in females with primary cancer of the cervix.

Materials and Methods

Patients and reference standards

In this prospective study we included 46 females consecutively hospitalized at the Department of Gynaecology and Obstetrics at the »Sestre milosrdnice« University Hospital Center in Zagreb. The study commenced in January 2006 and ended in December 2008. Interviews, clinical examination, transvaginal ultrasound (US) and laboratory findings were done at the Department of Gynaecology. MRI, computerised tomography (CT) scans, abdominal US and plain X-rays were performed at the Department of Diagnostic and Interventional Radiology. Pathohistological analysis was performed at the Ljudevit Jurak Clinical Pathology Department of the same hospital.

Females who met the following criteria were included in the study: older than 18 years of age, clinical findings suggestive of FIGO IIA and IIB stages and primary untreated cervical cancer⁶. Pregnant patients, patients who could not provide informed medical consent, patients with contraindications for MR examination (pacemakers, metallic prostheses, stents, claustrophobia and need to be immobilized during the examination), patients unwilling or unable to undergo contrast media-enhanced MRI and patients who were not considered surgical candidates for reasons of comorbidity were excluded.

The potential surgical candidates were all patients with clinically and/or MRI IIA stage of cervical uterine cancer selected by a consensus of the attending gynaecologist and radiologist.

The preoperative MR imaging features and clinical staging were correlated with the operative histopathological findings. All patients were examined and staged clinically by a single experienced gynaecologist based on the FIGO staging system⁶. Patients' age, family history and personal medical history were recorded in a personal interview done by the same doctor, before the examination. The symptoms taken in consideration were: vaginal

discharge, pain in the back, pelvis and upper parts of the legs.

We also recorded the laboratory findings: Erythrocyte sedimentation rate (ESR), erythrocyte and leukocyte count (EC and LC), creatinine and urea serum values, urine cytological analysis and urine culture stains. Pre-treatment measurements of tumor markers (carcinoma antigen (CA 125), squamous cell carcinoma antigen (SCC) and tissue polypeptide antigen (TPA)) were taken. Specular gynaecological exam, Papanicolaou (PAP) test and colposcopy were done in all patients according to previously published standard protocols^{10,11}. Endocervical curettage and target biopsy of the cervical tumor tissue were also performed in all patients and sent to PHD analysis¹¹.

Transvaginal ultrasound, plain X-rays, abdominal ultrasound and computerized tomography scans

Transvaginal US was done in all patients to detect the localisation and borders of the tumorous process. We used the Philips, HDI 5000 SonoCT system (101 Copperwood Way, Suite A, Oceanside, CA, United States, 2003) ultrasound machine with convex and transvaginal multifrequency probes. Abdominal and pelvic US as well as digitorectal examination were performed in all patients. Transvaginal US was done by the same gynaecologist who performed clinical examination.

Thoracic, abdominal and pelvic CT scans were done only in selected patients with suspected findings on plain chest X-rays and abdominal ultrasound examination. We used MSCT (16-slice Siemens Somatom Sensations, Siemens, Berlin, 2005) in direct transversal scans and three-dimensional (3D) reconstructions.

Magnetic resonance imaging

The MR imaging was performed on a high-field 1.5 T magnet system (Magnetom Avanto Harmony, Siemens, Erlangen, Germany, 2005). The patients had to empty urinary bladders before the exam because of possible artefacts. In case of claustrophobia or anxiety the patients were sedated. Five minutes before the exam an intramuscular spasmolytic (hyoscine butylbromide) was injected to avoid artefacts made by bowel movements and spasms. We carefully queried all patients for potential contraindications.

We applied »body« coil and phased-array MR coils. Standard MRI protocols were used: transverse, sagittal and frontal sections concordant with internal axis of the uterine cervix. First we determined the large field of view (FOV) in the frontal axis from 20–24 cm in order to plan further axis. Depending on the position of the uterus, we performed T1 and T2 weighted (T1 and T2W) spin-echo images and postcontrast T1 spin-echo images. In transversal sections we applied anterior and posterior saturation, and in sagittal and frontal sections we applied cranial and caudal saturation, to overtake better resolution.

In standard protocol we also used large FOV with single shot echo train spin echo. Eventually, we applied 10

ml of paramagnetic contrast media and started to scan 30 and 60 seconds later and made a delayed scan 5 minutes later. Slice thickness was from 3–6 mm, usually 5 mm. We recorded axial and sagittal T2WI, axial T1WI and postcontrast axial and sagittal T1WI. Images were processed on the working station with Integrated System for Structural Analysis (ISSA) software (Laboratory of Relational Algorithmics, Complexity and Learnability, Polytechnic University of Catalunya, Barcelona, Spain, 2000) and recorded on the film or compact disc (CD). We analysed the dimensions of the tumor, signal intensity characteristics, extension to anatomical structures of the uterine cervix, parametrial infiltration, possible infiltration of surrounding organs, invasion of regional lymph nodes and distant metastases.

Image interpretation

Plain X-ray images, abdominal US, CT and MR images for all patients were interpreted by the same radiologist who had 15 year experience in reading CT and MR images and 30 year experience in performing ultrasound and reading plain X-rays. All of the CT and MR imaging studies were distributed in digital (i.e. »soft copy«) form. The radiologist was blind to the patient's clinical information. MR staging was based on FIGO classification (Table 1).

Statistical analysis

Descriptive statistics were calculated for all variables. We presented frequencies and percentages for qualitative and means with standard deviations for qualitative variables. We calculated the accuracy, sensitivity and specificity of clinical examinations. The accuracy was computed as a portion of true positives divided by the sum of true positives and true negatives; sensitivity as a number of true positives divided by the sum of true positives and

false negatives, and specificity as a number of true negatives divided by the sum of true negatives and false positives.

Ethical considerations

All patients provided written informed consent prior to enrolment. The Ethics Committee of the »Sestre milosrdnice« University Hospital Center, Zagreb, Croatia, approved the study.

Results

Results of clinical examination

Forty six females, aged between 35 and 75 years ($X=54.5$; $SD\pm 8.9$ years) were clinically examined. We present selected clinical characteristics in Table 2.

Serum tumor markers (CA 125, SCC and TPA) were negative in all patients. Urine culture and urine cytological tests were considered negative in all 46 patients.

Gynaecological specular examination revealed macroscopic changes of the cervical mucosa in all 46 patients. PAP cervical smear test¹⁰ in all 46 patients confirmed carcinomatous cells. Colposcopic findings¹¹ and endocervical curettage¹¹ showed invasive carcinoma in all patients. Transvaginal ultrasound was performed in all 46 patients. The tumor was visualised and defined in 13/46 (28%) patients.

Enlarged pelvic lymph nodes were not observed. Infiltration of the upper third vaginal part was seen in 3/46 (6%) patients and the infiltration of other pelvic organs was not detected.

Digitorectal examination was done in all 46 patients. In 20/46 (43%) patients the palpable infiltration of parametrial structures was found, that was concordant with FIGO IIB clinical stage⁶.

TABLE 1
THE MAGNETIC RESONANCE (MR) STAGING OF CERVICAL CARCINOMA BASED ON THE PATHOLOGICAL INTERNATIONAL FEDERATION OF OBSTETRICS AND GYNECOLOGY (FIGO) STAGING^{6,12}

Stage	Pathology	MR findings
Stage 0	In situ carcinoma	Tumor not seen
Stage IA	Microinvasive carcinoma confined cervix, <7 mm in width	Tumor not seen or same as Ib
Stage IB	Clinically invasive carcinoma confined only to cervix stroma, >Ia	Moderately hyperintense mass on T2-weighted images
Stage IIA	Carcinoma extends beyond the cervix, no parametrial invasion	Mass disrupting the low signal intensity of the vaginal wall (upper two thirds)
Stage IIB	Carcinoma extends beyond the cervix with parametrial invasion	Abnormal signal intensity within the parametrial region
Stage IIIA	Extension of tumor into the lower third of vagina without pelvic sidewall extension	Mass disrupting the lower one-third of vaginal wall
Stage IIIB	Pelvic sidewall extension	Pelvic sidewall extension
Stage IVA	Bladder or rectal involvement	Loss of perivesical and perirectal fat planes, invasion of the bladder or rectum
Stage IVB	Distant organ metastasis	Distal organ metastasis

TABLE 2
SELECTED CLINICAL CHARACTERISTICS OF 46 FEMALE PATIENTS ACCORDING TO INTERNATIONAL FEDERATION OF OBSTETRICS AND GYNECOLOGY (FIGO) STAGING^{6,12}

Clinical characteristics	Number of patients with clinical FIGO IIA classification	Number of patients with clinical FIGO IIB classification	Total number of patients	%
Blood-stained vaginal discharge for last 3–6 months	13	19	32	72
Family history of uterine cervical cancer	2	1	3	6
Positive test for HPV	8	2	10	22
Palpable infiltration of parametrial structures by digitorectal examination	0	20	20	43
Presence of back pain	2	6	8	17

Abdominal and pelvic US scan was performed in all 46 patients and no infiltration of nearby organs or enlarged lymph nodes were displayed. There was no ureteral dilatation seen. Two patients had suspected liver focal lesions.

Plain X-rays were done in all 46 patients and suspected pulmonary infiltrations were found in 4 patients.

CT scan of the chest, abdomen and pelvis was done in 6/46 (13%) mentioned patients with suspected pulmonary and liver focal lesions but secondary lesions and infiltrations on the liver or chest were not found. The tumor was clearly visualised in 3/46 (6.5%) patients, with the FIGO IIB stage. The extension of the uterine cervical cancer on other pelvic organs was not found. Lymph node enlargement was positive in 3 patients with FIGO IIB group.

According to FIGO classification, we found positive clinical findings for stage IIA in 26/46 (55.5%) and stage IIB in 20/46 (44.5%) patients. All 46 patients were sent to MR examination of the uterus.

Results of magnetic resonance examination

Tumors were displayed in all 46 patients. In the IIA FIGO group the largest tumor was 32 mm in diameter. All tumors were homogenous, without the necrotic zones

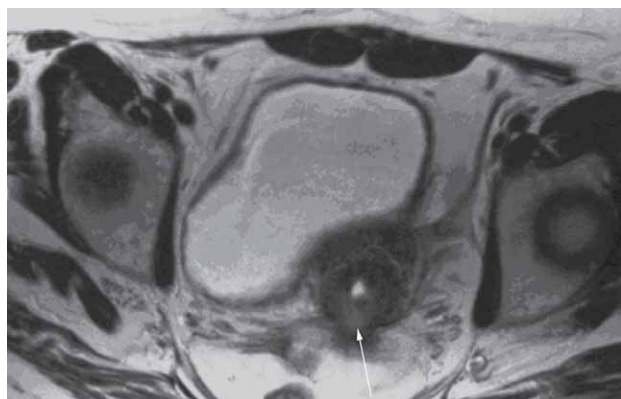


Fig 1. International Federation of Gynaecology and Obstetrics (FIGO IIA) stage of cervical cancer. Transversal T2WI. Posterior extension of the tumor mass. Parametria are not infiltrated.

or haemorrhage. Parametrial infiltration was not found in any of the patients. Urinary bladder, rectum, pelvic muscles and pelvic spaces were unremarkable in all patients.

In the IIB FIGO group the largest tumor was 39 mm in diameter. In 3 cases we found inhomogeneous tumor structure. One side parametrial infiltration was seen in 8/20 (40%) patients and both sides in 5/20 (25%). Enlarged pelvic lymph nodes were found in 12/20 (60%), but without making a specific diagnosis of metastatic lymph node changes.

The tumors didn't infiltrate other surrounding organs. FIGO MR modified classification⁸ confirmed stage IIA in 30/46 (66.6%) (shown in Figures 1 and 2) and stage IIB in 16/46 (33.4%) patients (shown in Figures 3 and 4).

Results of cervical cancer surgery

Surgery (Wertheim radical hysterectomy with bilateral pelvic and selective para-aortic lymphadenectomy)¹³ was performed in 33/46 (71%) patients, 26 of whom had

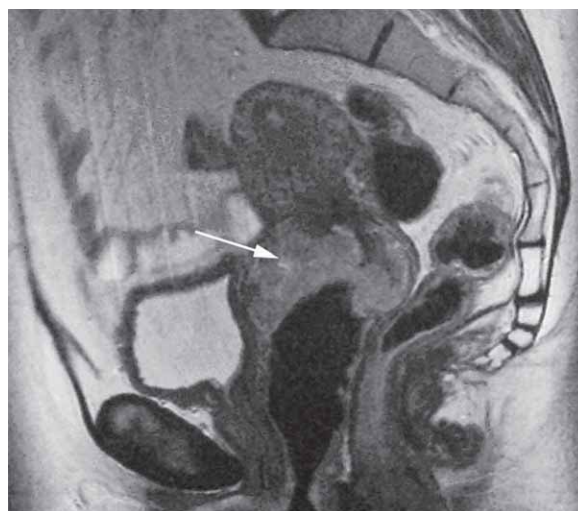

Fig 2. International Federation of Gynaecology and Obstetrics (FIGO IIA) stage of cervical cancer. Sagittal T2WI. Tumor extension to urinary bladder anteriorly, to rectum posteriorly and inferiorly infiltrates the upper third of vagina. No parametrial infiltration was found.

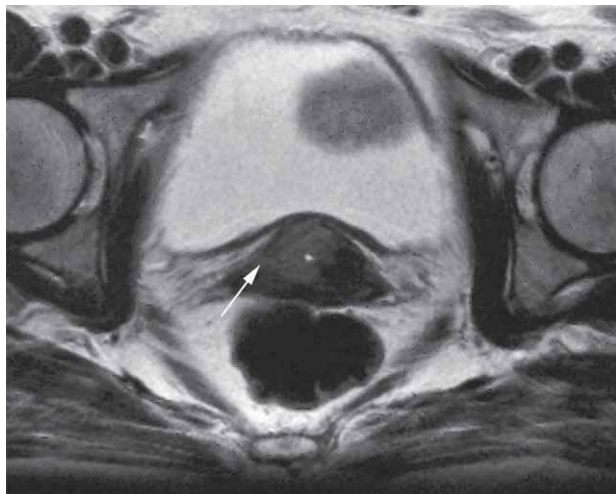


Fig 3. International Federation of Gynaecology and Obstetrics (FIGO) IIB stage of cervical cancer. Transversal T2WI: the tumor displays a higher signal intensity than the surrounding tissue. Parametrial infiltration on the right (arrow).

clinically confirmed FIGO IIA stage. Of those 26, MR confirmed IIA stage in 23 and IIB stage in 3 patients. In 7 surgically treated patients the clinical finding was congruent with stage IIB, but MR examination confirmed stage IIA. The postoperative course in all patients was satisfactory without complications and without a single fatality. We removed the parametria with careful preparation of blood vessels and prepared the vagina.

We explored regional lymph nodes with surrounding fat tissue. The same was done with pelvic lymph nodes. All surgically removed material was sent to pathohistological examination.

Results of pathohistological analysis

The clinical FIGO IIA stage was pathohistologically⁶ confirmed in 29/33 (88.5%) operated patients. In 26/33 (78%) planocellular cancer was found, in 6/33 (19%) adenocarcinoma was confirmed and in 1/33 (3%) mucopidermoid carcinoma was detected. Infiltration of locoregional lymph nodes was shown in 3 patients with FIGO IIB stage and in 3 with FIGO IIA stage. In 2 patients with FIGO IIB stage the pelvic lymph nodes were infiltrated. Parametrial infiltration was positive in 4 patients, unilateral in 2 and bilateral in 2.

Correlation of FIGO clinical, magnetic resonance and pathohistological staging in 33 operated patients

The sensitivity and specificity of clinical examination was 78% and 69% and for MRI 96% and 75%, respectively, compared with PHD findings, in 33 operated patients. The overall accuracy of tumor staging by clinical examination was 79% (26 of 33 patients) and for MRI 90.9%. One patient (3%) was overstaged by MRI and 2 (6%) were understaged.

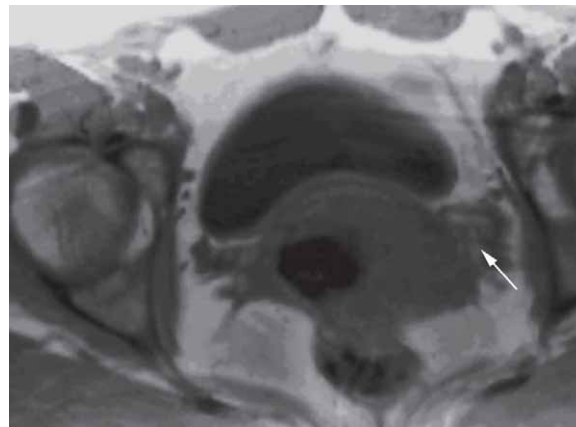


Fig 4. International Federation of Gynaecology and Obstetrics (FIGO IIB) stage of cervical cancer. Transversal postcontrast T1WI. Bilateral parametrial infiltration (arrow).

Discussion

The most important of our findings is 90.9% accuracy of MRI in comparison to pathohistological postoperative findings. Recent studies report different sensitivity and specificity of MRI, depending on the strength of high-field MR machine, application of coils, and sequences and pre and postcontrast protocols. Boss and colleagues¹² described fast dynamic enhanced MR imaging. They performed scanning 40 and 60 seconds after contrast application and delayed scan after 5 minutes. The accuracy of MRI was 95%. According to numerous studies, the best images to demonstrate cervical neoplasms are T2WI^{8,12,14,15}.

Cervical carcinoma has intermediate signal intensity at T2WI and is seen as a mass disrupting low-signal intensity cervical stroma⁸. Van Vierzen analyzed pre and postcontrast T1WI, T2WI and dynamic postcontrast T1WI¹⁶. Postcontrast T1W image and T2W image were more accurate than T1W. The cervical mass can demonstrate a wide variety of morphological features and may be exophytic, infiltrating or endocervical⁸. Preidler and coworkers used endorectal coil and the results were better than results achieved with body coil¹⁷. But there are also opposite opinions, that the tumor detection, tumor sizing, and evaluation of locoregional extent is not influenced by magnetic field strength or the type of coil used^{18,19}. According to our experience from the present study we suggest the application of the following MR protocol in all clinically staged FIGO IIA and IIB patients: T1W, T2WI and postcontrast dynamic T1WI after 3 and 60 seconds and after 5 minutes, performed on 1.5T MR machine.

In our study the MRI finding was underestimated in 6% of cases and overestimated in 3% of cases. Boss et al reviewed 12 studies describing staging accuracy with MR imaging¹².

The mean percentage of overstaged cases on MRI was 14% (range 2–53%) and understaged cases 8% (0–17%)¹². Our findings are consistent with most published studies.

More studies compared the accuracy of CT and MR in the assessment of parametrial infiltration^{20,21}. Hedvig Hricak and a group of coauthors stated that MR imaging was significantly better than CT for tumor identification and detection of parametrial invasion²⁰.

We didn't use the CT imaging in the staging of cervical cancer in our study because of the hazards of X-rays²². We performed CT scan of the thorax and abdomen in selected patients with suspected secondary lesions on plain X-ray images or abdominal ultrasound findings. The CT scan findings were negative and distant metastatic disease was not assessed in any of our patients.

We didn't perform CT/PET in our patients, although this technique is emerging as the modality of choice for evaluation of distant metastatic disease with published sensitivity and specificity rates of 100% and 94%, respectively^{23,24}. The reason why we didn't use it were negative CT findings in selected patients and the fact that distant metastases usually occur in patients with disease recurrence²⁵ and all of our patients had a primary diagnosed cervical cancer. Recurrence is defined as the development of tumor 6 months or more after disease regression⁹.

In recent years the preservation of reproductive function has been a major concern for physicians that attempted to develop a less aggressive surgery⁷. Some experts found potential areas for revision of the current FIGO system because it may lack accuracy in stratifying patient prognosis⁷. They suggest that the FIGO definition (1995) of early cervical cancer should be improved by adding more details, including lymph node status and tumor size (less and more than 2 cm) in future classification⁷. We precisely measured the size of tumor and the largest tumor in group IIA was 39 mm in diameter, while in IIB group it was 48 mm. That helped us in tumor staging.

The problem that should be considered is the analysis of lymph nodes. We found enlarged pelvic lymph nodes in both groups of patients, but we didn't find any specific morphological characteristics that could distinguish metastatic lymph nodes from »reactive« lymph nodes. According to Follen et al. MRI relies on lymph node size as the primary criterion for determining the presence of metastatic disease within a lymph node²². Lymph nodes larger than 1 cm in the short-axis dimension are considered abnormal²². However, it is not an ideal criterion for determining the presence or absence of disease within a lymph node. Central necrosis within a lymph node is a useful predictor of metastatic disease²⁶. We didn't find necrotic lymph nodes in our patients.

Squamous cell carcinoma is the most common malignancy affecting the cervix and the third most common gynecologic malignancy²⁷, which constitutes 80–85% of all cases²⁸. In our patients the squamous cell carcinoma was detected in 78% of women that is concordant with published data²⁹. Less common malignant neoplasms of the uterine cervix include adenocarcinoma, which constitutes 15–20% of cases in the literature²⁷, then adenoma malignum, lymphoma, rhabdomyosarcoma, and small

cell carcinoma. In our study 19% of patients presented with adenocarcinoma and 3% with mucoepidermoid carcinoma. MRI features of cervical adenocarcinoma are similar to squamous cell carcinoma²⁷. The tumor mass tends to be more hyperintensive on T2WI and is more aggressive with a greater likelihood of metastatic disease²⁷. We didn't find any specific MRI characteristics that can predict the pathohistological form of the tumor.

The accuracy of clinical findings according to FIGO classification and pathohistological finding was 79%. The greatest difficulties in clinical evaluation of cervical cancer are the assessment of invasion of the parametrium and the pelvic side walls, the estimation of tumor size and the evaluation of the lymph node metastases^{14,12}. When correlated with surgical staging, clinical staging has an error rate of 26–66%²¹.

Surgical staging is the ideal method to determine the extent of disease histopathologically. Although radiation therapy is an equally effective treatment for women with early-stage disease as demonstrated through a randomized trial comparing primary surgery with primary radiotherapy in women with stage IB-IIA, radical hysterectomy is generally considered to be the treatment of choice for young, healthy women, allowing preservation of ovarian function³⁰. Usually, type III of radical hysterectomy is performed that consists of hysterectomy and removal of lateral parametria, sacrouterine ligaments and the upper third of vagina¹³. In IIB stage of disease, if the patient is not going primarily to radiochemotherapy the type IV of operation is usually committed. It includes the type II plus removal of periureteral tissue and proximal three quarters of vagina¹³. Radiation therapy alone or combined with chemotherapy is preferred for stages IIB or higher if the lesions are greater than 4 cm⁸. In all of our patients we decided to perform Wertheim radical hysterectomy with bilateral pelvic and selective para-aortic lymphadenectomy. Since minimally invasive surgery has progressed in the last three decades³¹, radical abdominal hysterectomy remains a standard of care³². The decision of therapeutical choice is based on a multidisciplinary approach: the radiological, oncological, gynecological and pathological opinion. In selected cases, abdominal surgeon and urologist are included.

The limitation of our study was that we didn't include women with early stage of cancer – IB. It is a challenge for gynecologists and radiologists to detect more subtle signs of cervical cancer. Another possible limitation was the lack of comparison between transvaginal ultrasound, clinical finding, MRI and pathohistological finding. Transvaginal ultrasound is a harmless and inexpensive method that can be repeated. Further investigation and comparison of TVU with other imaging methods is needed. The low prevalence of HPV could be explained with a small sample-size of our study.

Conclusion

MRI examination is better than clinical examination in staging of cervical carcinoma with 90.9% versus 79.0%

accuracy rate. Presently, this method is easier to reach and we recommend the incorporation of this technique in the preoperative FIGO staging of cervical cancer in Croatia. We suggest the application of the following MR protocol in all clinically staged FIGO IIA and IIB patients: T1W, T2WI and postcontrast dynamic T1WI after 3 and 60 seconds and after 5 minutes, performed on 1.5T MR machine.

REFERENCES

1. CORUSIC A, SKRGATIC L, MAHOVLIC V, MANDIC V, PLANIC P, KARADZA M, Coll Antropol, 34 (2010) 301. — 2. ZNAOR A, STRNAD M, Coll Antropol, 31 Suppl 2 (2007) 37. — 3. CROATIAN NATIONAL CANCER REGISTRY-CROATIAN NATIONAL INSTITUTE OF PUBLIC HEALTH: CANCER -INCIDENCE IN CROATIA (2007), Bulletin No. 32., accessed 15.5.2013. Available from: URL: <http://www.hzjz.hr/cancer/bilten07.htm>. — 4. ZNAOR A, BABIC D, CORUSIC A, GRCE M, MAHOVLIC V, PAJTLER M, SERMAN A, Lijec Vjesn, 129 (2007) 158. — 5. FERLAY J, PARKIN DM, STELIAROVA-FOUCHER E, Eur J Cancer, 46 (2010) 765. DOI: 10.1016/j.ejca.2009.12.014. — 6. BENEDET JL, BENDER H, JONES H, NGAN HY, PECORELLI S, Int J Gynaecol Obstet, 70 (2000) 209. — 7. PETIGNAT P, LOUBEYRE P, Expert Rev Anticancer Ther, 8 (2008) 1015. DOI: 10.1586/14737140.8.7.1015. — 8. NICOLET V, CARRIGNAN L, BOURDON F, PROSMANNE O, Radiographics, 20 (2000) 1539. — 9. REZVANI M, SHAABAN A, Clin Obstet Gynecol, 52 (2009) 94. DOI: 10.1097/GRF0b013e31819617f1. — 10. SIMUNOVIC V, Ginekologija (Medicinska biblioteka, Zagreb, 2001). — 11. ZUHER MN, Precursors of invasive cervical squamous cell carcinoma. In: ZUHER MN Cytopathology (Little, Brown and Company, Boston, New York, Toronto, London, 1985). — 12. BOSS EA, BARENTSZ JO, MASSUGER LF, BOONSTRA H, Eur Radiol, 10 (2000) 256. — 13. QUERLEU D, MORROW CP, Lancet Oncol, 9 (2008) 297. DOI: 10.1016/S1470-2045(08)70074-3. — 14. SHEU MH, CHANG CY, WANG JH, YEN MS, Eur Radiol, 11 (2001) 1828. — 15. POSTEMA S, PATTYNAMA PM, BROKER S, VAN DER GEEST RJ, VAN RIJSWIJK CS, BAPTIST TRIMBOS J, Clin Radiol, 53 (1998) 729. — 16. VAN VIERZEN PB, MASSUGER LF, RUYSS SH, BARENTSZ JO, Clin Radiol, 53 (1998) 183. — 17. PREIDLER KW, TAMUSSINO K, SZOLAR DM, RANNER G, EBNER F, Invest Radiol, 31 (1996) 458. — 18. HRICAK H, QUIVEY JM, CAMPOS Z, GILDENGORIN V, HINDMARSH T, BIS KG, STERN JL, PHILLIPS TL, Int J

Acknowledgements

The authors kindly thank Professor Goran Grubisic, MD, PhD, of the University of Zagreb, Croatia, School of Medicine, for his guidance and support during all stages of this study. We also wish to thank Arijana Pavelić, Jasminka Blaha and Marija Fijucek from the University Hospital for Infectious Diseases, Zagreb, Croatia, for technical help in manuscript preparation.

Radiat Oncol Biol Phys, 27 (1993) 791. — 19. POSTEMA S, PETERS LA, HERMANS J, TRIMBOS JB, PATTYNAMA PM, J Comput Assist Tomogr, 20 (1996) 807. — 20. HRICAK H, GATSONIS C, COAKLEY FV, SNYDER B, REINHOLD C, SCHWARTZ LH, WOODWARD PJ, PANNU HK, AMENDOLA M, MITCHELL DG, Radiology, 245 (2007) 491. — 21. OZSARLAK O, TJALMA W, SCHEPENS E, CORTHOUS B, OP DE BEECK B, VAN MARCK E, PARIZEL PM, DE SCHEPPER AM, Eur Radiol, 13 (2003) 2338. — 22. FOLLEN M, LEVENBACK CF, IYER RB, GRIGSBY PW, BOSS EA, DELPASSAND ES, FORNAGE BD, FISHMAN EK, Cancer, 98 (2003) 2028. — 23. LOFT A, BERTHELSEN AK, ROED H, OTTOSEN C, LUNDEVALL L, KNUDSEN J, NEDERGAARD L, HOJGAARD L, ENGELHOLM SA, Gynecol Oncol, 106 (2007) 29. — 24. RISUM S, HOGDALL C, LOFT A, BERTHELSEN AK, HOGDALL E, NEDERGAARD L, LUNDEVALL L, ENGELHOLM SA, Gynecol Oncol, 105 (2007) 145. — 25. METSER U, HAIDER MA, KHALILI K, BOERNER S, AJR Am J Roentgenol, 180 (2003) 765. — 26. NARAYAN K, Int J Gynecol Cancer, 15 (2005) 573. — 27. CHATURVEDI AK, KLEINERMAN RA, HILDESHEIM A, GILBERT ES, STORM H, LYNCH CF, HALL P, LANGMARK F, PUKKALA E, KAJSER M, ANDERSSON M, FOSSA SD, JOENSUU H, TRAVIS LB, ENGELS EA, J Clin Oncol, 27 (2009) 967. DOI: 10.1200/JCO.2008.18.4549. — 28. BERRINGTON DE GONZALEZ A, SWEETLAND S, GREEN J, Br J Cancer, 90 (2004) 1787. — 29. BOYLE P, FERLAY J, Ann Oncol, 16 (2005) 481. — 30. LANDONI F, MANEO A, COLOMBO A, PLACA F, MILANI R, PEREGO P, FAVINI G, FERRI L, MANGIONI C, Lancet, 350 (1997) 535. — 31. SCHLAERTH AC, ABURUSTUM NR, Oncologist, 11 (2006) 895. — 32. PAHISA J, MARTINEZ-ROMAN S, TORNE A, FUSTE P, ALONSO I, LEJARCEGUI JA, BALASCH J, Int J Gynecol Cancer, 20 (2010) 173. DOI: 10.1111/IGC.0b013e3181bf80ee.

K. Visković

University of Zagreb, University Hospital for Infectious Diseases, Department of Radiology and Ultrasound, Mirogojska cesta 8, 10000 Zagreb, Croatia
e-mail: viskovich@gmail.com

PRIMARNI KARCINOM GRLIĆA MATERNICE: KORELACIJA PREOPERATIVNOG NALAZA MAGNETSKE REZONANCE, STUPNJEVANJA KLINIČKOG PREGLEDA PO FIGO KLASIFIKACIJI I PATOHISTOLOŠKOG NALAZA

SAŽETAK

Najčešće korišten sustav stupnjevanja karcinoma grlića maternice bazira se na međunarodnoj klasifikaciji karcinoma vrata maternice (FIGO – International Federation of Gynaecology and Obstetrics). Magnetska rezonanca (MR) je prihvaćena kao optimalna slikovna metoda u evaluaciji glavnih prognostičkih čimbenika te u određivanju terapijskih postupaka. Cilj ovog istraživanja bila je usporedba preoperativnog kliničkog nalaza po FIGO klasifikaciji te nalaza MR-a s postoperativnim patohistološkim nalazom u žena s primarnim karcinomom grlića maternice. U ovu smo pros-

pektivnu studiju uključili 46 žena hospitaliziranih na Odjelu za ginekologiju i porodništvo Kliničke bolnice »Sestre milosrdnice« u Zagrebu. Sve su ispitanice obavile razgovor, klinički pregled, transvaginalni ultrazvuk i magnetsku rezonancu. U odabranih ispitanica učinjen je kirurški zahvat i korelacija patohistološkog nalaza s kliničkim nalazom stupnjevanom po FIGO klasifikaciji i nalazom MR-a. Sukladno kliničkom stupnjevanju po FIGO klasifikaciji, pozitivan nalaz za stupanj IIA karcinoma grlića vrata maternice utvrđen je u 24/46 (55,5%) ispitanica, dok je stupanj IIB utvrđen u 20/46 (44,5%) ispitanica. Klasifikacija MR nalaza modificirana po FIGO klasifikaciji potvrdila je stupanj IIA u 30/46 (66,6%) i stupanj IIB u 16/46 (33,4%) ispitanica. Kirurški zahvat (radikalna histerektomija po Wertheimu s bilateralnom zdjeličnom i selektivnom paraaortalnom limfadenektomijom) učinjena je u 33/46 (71%) ispitanica s klinički, MR-om i patohistološki potvrđenim karcinomom grlića maternice: u 26 ispitanica s FIGO IIA i u 7 s FIGO IIB stupnjevanima. Pregled MR precizniji je u usporedbi s kliničkim pregledom s ukupnom točnošću od 90,9% u odnosu na 79%. Predlažemo sljedeći protokol pregleda MR-om u svih bolesnica s klinički utvrđenim stupnjem FIGO IIA: T1 mjerena slika, T2 mjerena slika i postkontrastne dinamičke T1 mjerene slike nakon 3 sekunde, 60 sekundi i 5 minuta učinjene na MR aparatu snage 1,5 T.